



Understanding Chromosome & Gene Disorders

15q24 microdeletion syndrome



rarechromo.org

Sources.

The information in this leaflet is drawn partly from the published medical literature.

The first-named author and publication date are given to allow you to look for the abstracts or original articles on the internet in PubMed (<http://www.ncbi.nlm.nih.gov/pubmed/>). If you wish, you can obtain most articles from Unique.

In addition, this leaflet draws on information from a survey of members of Unique conducted in 2011, referenced Unique.

When this leaflet was written Unique had 15 members with a 15q24 microdeletion. These members range in age from a baby to an adult aged 20 years. There are 33 people described in the medical literature, including four adults, aged 16-29 years.

15q24 microdeletion syndrome

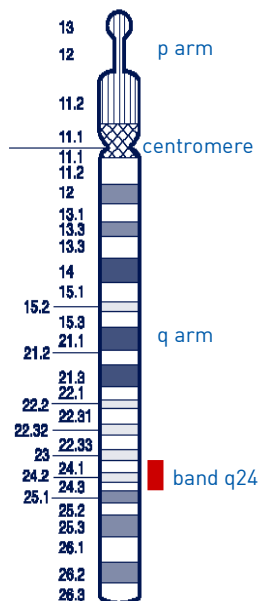
A 15q24 microdeletion is a very rare genetic condition in which a tiny piece is missing from one of the 46 chromosomes – chromosome 15.

Chromosomes are made up mostly of DNA and are the structures in the nucleus of the body's cells that carry genetic information (known as genes), telling the body how to develop, grow and function. Chromosomes usually come in pairs, one chromosome from each parent. Of these 46 chromosomes, two are a pair of sex chromosomes, XX (a pair of X chromosomes) in females and XY (one X chromosome and one Y chromosome) in males. The remaining 44 chromosomes are grouped in 22 pairs, numbered 1 to 22 approximately from the largest to the smallest. Each chromosome has a short (p) arm (shown at the top in the diagram below) and a long (q) arm (the bottom part of the chromosome). People with a 15q24 microdeletion have one intact chromosome 15, but the other is missing a tiny piece from the long arm and this can affect their learning and physical development. However, a child's other genes and personality also help to determine future development, needs and achievements.

Looking at chromosome 15q

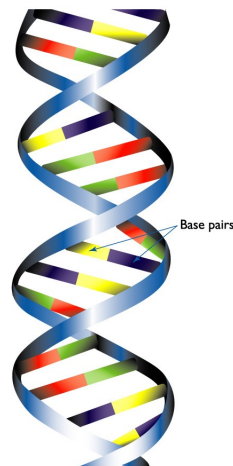
People who have missing material on a chromosome are said to have a deletion but when the amount is so small that it can't be seen even under a high-powered microscope, it is called a microdeletion. The 15q24 microdeletion can be found using molecular techniques such as multiplex ligation-dependent probe amplification (MLPA) and array comparative genomic hybridisation (array-CGH) or by cytogenetic fluorescent *in situ* hybridisation (FISH) techniques using fluorescent DNA probes targeted to gene markers within the involved chromosome 15q24 region. These techniques show whether particular genes are present or not.

It is believed that the effects are caused by the presence of only one copy of these genes instead of two, as expected normally. The 15q24 region is denoted by the red bar on the diagram on the right. Band 15q24 contains around 3.5 million base pairs. This sounds a lot but it is actually quite small and is only 3.5 per cent of the DNA on chromosome 15. Chromosome 15 has around 100 million base pairs and is about three per cent of the total DNA in our cells. Base pairs are the chemicals in DNA that form the ends of the 'rungs' of its



ladder-like structure. The size of the microdeletion is variable and in different people the region where the chromosome has broken (the 'breakpoints') is different (Van Esch 2009).

1 base pair = bp
1,000 base pairs = 1kb
1,000,000 base pairs = 1Mb



How common is 15q24 microdeletion syndrome?

15q24 microdeletions are often referred to as **15q24 microdeletion syndrome** and were first described in 2007. The overall incidence of the 15q24 microdeletion in the general population is likely to be in the region of 1 in 42,000. The incidence in individuals with autism spectrum disorder is predicted to be higher at 1-2 in 1000 (McInnes 2010, Magoulas 2012).

At present 33 people with 15q24 microdeletion syndrome have been described in the medical literature. Although you would expect equal numbers of boys and girls, 25 are boys (76 per cent); the reasons for this are not yet clear, but may just reflect the small sample size. It is also possible that the genital anomalies, found in boys in particular, may lead to a higher referral rate for genetic testing amongst boys. Amongst Unique members, nine are boys (60 per cent). The features seen in the girls do not appear to differ from those observed in boys (with the exception of the genital findings). Deletions in the 15q24 region account for less than 0.5 per cent of cases sent for molecular genetic testing (Cushman 2005; Sharp 2007; Andrieux 2009; El-Hattab 2009; Mefford 2011; Magoulas 2012; Unique).

Age at diagnosis

The age at which 15q24 microdeletion syndrome is diagnosed ranges from newborns to 29 years old. The average age at diagnosis is around 10 years old (Mefford 2011; Unique).

Results of the chromosome test

Your geneticist or genetic counsellor will be able to tell you about the point where the chromosome has broken in your child. With 15q24 microdeletion syndrome, the results are likely to read something like the following example:

arr[hg19] 15q24.1q24.2 (70819114-73321461)x1

arr

The analysis was by array-CGH

hg19

Human Genome build 19. This is the reference DNA sequence that the base pair numbers refer to. As more information about the human genome is found, new "builds" of the genome are made and the base pair numbers may be adjusted

15q24.1q24.2 The chromosome involved is 15. The chromosome has two breakpoints, one in band 15q24.1 and one in band 15q24.2 and material between these two breakpoints is missing

(70819114-73321461)x1

The base pairs between 70,819,114 (around 71Mb) and 73,321,461 (around 73Mb) have been shown to be deleted. Take the first long number from the second and you get 2,502,347 (2Mb). This is the number of base pairs that are deleted. x1 means there is one copy of these base pairs, not two – one on each chromosome 15 – as you would normally expect

Emerging phenotype: what to expect

When only very small numbers of people have been identified, we can't yet be certain what the full range of possible effects of the microdeletion are. The features that are most striking and most common are:

- Growth delay in the womb and/or afterwards leading to short stature
- Facial features, for example, microcephaly (small head) and a high forehead
- Children are likely to need support with communication and learning. Speech delay can be significant. The amount of support needed by each child will vary, although most benefit from supportive services for special needs
- Lax (hypermobile) joints and hypotonia (low muscle tone or floppiness) affecting gross and fine motor skills. Physiotherapy and occupational therapy are beneficial
- Vision - squints are common
- Minor hand and feet anomalies
- Minor genital anomalies
- Hearing loss

Less common features are:

- Seizures
- Heart defects
- Hernias

What is the outlook?

We can't be sure yet but there appears to be no reason why people who are healthy should not enjoy a normal lifespan. The outlook for individuals with 15q24 deletion syndrome will vary from person to person. This is in large part due to the extent of any birth defects. In general, the majority of individuals do not typically have life-threatening organ defects. Several adults have been described in the medical literature (see page 16). There have been one or two reports of abnormal growth of cells, resulting in a tumour (neoplasia). It is not known if there is a direct relationship between 15q24 deletion and the neoplasias described, but extra vigilance may be required (Magoulas 2012).

Pregnancy

Most mothers carrying babies with a 15q24 microdeletion experienced no pregnancy problems, had a normal delivery and only discovered their baby was affected after the birth. There is information available on nineteen pregnancies of mothers carrying a baby with a 15q24 microdeletion. Seven had no pregnancy problems and no unusual findings on ultrasound scans. One mother had some bleeding at 14 weeks. Six babies had intrauterine growth retardation (IUGR). This is a term used to describe babies whose growth in the womb has slowed resulting in babies that are smaller than expected for the number of weeks of pregnancy. Two babies with IUGR also showed unusual findings on ultrasound scans including a heart defect and a single umbilical artery (in both babies) and one had an unusually located (ectopic) right kidney.

One baby was delivered at 38 weeks due to the mother having preterm hydorrhoea (watery discharge from the uterus). Two mothers had polyhydramnios (an unusually high volume of amniotic fluid). Another baby had a heart defect suspected during pregnancy and had an amniocentesis test during pregnancy which failed to detect the 15q24

microdeletion (due to the small size of the microdeletion) (Klopocki 2008; Andrieux 2009; El-Hattab 2009; Magoulas 2012; Unique).

Newborn

Newborns with 15q24 microdeletion syndrome may not have any signs or symptoms. However, there may be some physical signs early on. Infants may have low muscle tone (hypotonia) and boys may have a specific genital anomaly called hypospadias (see page 11). Some people with 15q24 microdeletion syndrome were found to have a hernia (see page 11). One *Unique* boy had shallow 'clicky hips' (the hip socket is so shallow that the ball of the hip can dislocate easily) at birth which resolved by 8 months (Unique).

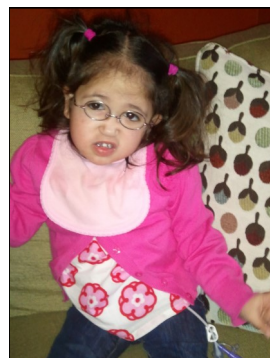Feeding and growth

Babies are often, but not always, born small and light for dates. Birthweights recorded at Unique and in the published medical literature show a considerable variation with an average of 3.03 kilos (6lb 11oz). Many babies have a normal or even high birth weight, however, around a third (6/18) had a low birth weight (below 2.6 kilos or 5lb 12oz) at term (Andrieux 2009; Masurel-Paulet 2009; Van Esch 2009; McInnes 2010; Mefford 2011; Magoulas 2012; Unique).

Feeding difficulties appear to be common in those with a 15q24 microdeletion and a number of babies (8/12) are described as having feeding difficulties. The hypotonia that is common in babies with 15q24 microdeletions can lead to difficulties with sucking and swallowing, and/or latching onto the breast. Seven of the mothers surveyed by Unique attempted to breastfeed, three of whom were successful. Of those mothers that encountered difficulties breastfeeding a number still fed their babies expressed breastmilk. One baby has a cleft palate (an opening in the roof of the mouth). A number of babies (4/10) have a high palate. A cleft or high palate can mean the action of sucking and swallowing is difficult. Two of the babies surveyed by Unique benefited from having a temporary nasogastric tube (NG-tube, passed up the nose and down the throat). One Unique baby (and one in the medical literature) had a gastrostomy tube placed (a G-tube, feeding direct into the stomach) fitted at 3 months and at 7 months a gastrostomy-jejunostomy (a GJ-tube, a tube inserted into the stomach like a G-tube but with another port that tunnels through the stomach into the intestine) (Sharp 2007; El-Hattab 2009; Masurel-Paulet 2009; Van Esch 2009; McInnes 2010; Mefford 2011; Unique).

The hypotonia can also affect their food passage and contribute to gastro-oesophageal (GO) reflux (in which feeds return readily up the food passage). Five out of nine children surveyed by Unique had GO reflux; two cases in the medical literature had GO reflux (Mefford 2011). GO reflux can generally be well controlled by giving feeds slowly, positioning a baby semi-upright for feeds and where necessary raising the head of the end of the bed for sleeping. Feed thickeners and prescribed medicines to inhibit gastric acid may control reflux. If these measures are not enough, some babies benefit from a fundoplication, a surgical operation to improve the valve action between the stomach and food passage (Unique).

Some older babies and toddlers have trouble chewing and can choke or gag on lumps in food. As a result children may continue to eat soft foods (or foods cut up into small



3 years

longer than their peers and each meal may take some time (Unique).

“ He had serious temporary feeding problems in the first 3 weeks. He breastfed on demand but slept a lot and was not able to put on any weight. He started putting on weight after taking expressed breast milk in a bottle every 2 hours around the clock. At 4 months went back to 100% breastfeeding with good weight gain until solids started at 6 months. With solids the reflux and constipation became more apparent and he now has energy supplements added to his food because of poor weight gain – 14 months

“ She breastfed until she was 12 months. She gagged easily on milk and then food but now does well with food. She is highly allergic to wheat – 2½ years

“ Enlarged tonsils made swallowing hard. As an infant, she would spit up a lot due to hypotonia. If she was just fed a bottle and was laid down, it would just pour out – 3 years

“ No feeding problems. She was breastfed for 18 months – 5 years

“ She is a very fussy eater and although she eats well she has a limited diet and tends to like strong flavours e.g. mature cheese not mild. She does tend to chew a little now but this is only recently and so food had to be soft or cut up small – 6½ years

“ He has a tendency to overstuff his mouth. He uses liquids to dissolve the food to the point that he can swallow it, although he can chew – 7 years

Some children, although not all, have growth delay resulting in short stature (15/33). Microcephaly (a small head) has also been frequently found (12/35), although nine individuals have a large head. Ten people (age range 6-33 years) have developed obesity; eight people are described as being underweight (Klopocki 2008; El-Hattab 2009; Van Esch 2009; Mefford 2011; Magoulas 2012; Unique).

Appearance

Children and adults with 15q24 microdeletion syndrome may look similar. They often have a high forehead with a high hairline, a long face with full cheeks. They have broad eyebrows and widely spaced eyes (hypertelorism) with an extra fold of skin covering the corner of the eye (epicanthal folds). They may have a smooth upper lip (philtrum) and a full lower lip (Mefford 2011; Magoulas 2012).

“ According to the geneticist's report: frontal bossing; long, narrow philtrum; narrow mouth; bilateral epicanthal folds. According to everyone: gorgeous brown eyes; devastating smile and very handsome!

Development: sitting, moving, walking (gross motor skills)

Often gross motor skills are affected in those with a 15q24 microdeletion and this means that it may take a little longer for children to roll over, sit, crawl and walk. From the limited information available, children sat unaided between the ages of 6 months and two and a half years (average 14 months). Babies started to crawl between 11 and 18 months (average 16 months). Independent walking was mastered by most between 18 months and three and a half years (average two years and four months). Children are often described as having an unusual gait and may tire very easily. One girl has not mastered independent walking at three and a half years but is able to sit and can roll to get around the room. Children may need considerable support while learning to walk (Klopocki 2008; Masurel-Paulet 2009; Van Esch 2009; McInnes 2010; Mefford 2011; Magoulas 2012; Unique).

around two-thirds of those with a 15q24 microdeletion. Physiotherapy has proved beneficial to many children. Difficulties with hand-eye co-ordination, planning and organisation and poor balance can also contribute to these delays. The continuing difficulties with balance mean that some children are unsteady on their feet and fall easily. One Unique girl practises yoga to improve her balance and another is using core workouts, with jumping exercises and a balance beam to improve her strength and co-ordination (McInnes 2010; Mefford 2011; Magoulas 2012; Unique).

“ He is not yet able to consistently roll on to his front at 14 months, but has managed once or twice

“ She sits well and walks OK but is unsteady and falls frequently. We have found leg orthotics, occupational therapy, physiotherapy, horse-back riding and a therapy ball useful – 2½ years

“ She can climb stairs but cannot walk unaided. She can sit up but if she gets tired she will fall over. She can crawl for short periods of time – 3 years

“ She has very severe hypotonia and she cannot walk, crawl or sit for very long. She gets tired easily from physical exertion. She can roll and loves to do this – 3½ years

“ His hypotonia was severe; he could not hold up his head until he was 4 months old. Now, with the help of physiotherapy (core body workouts) and occupational therapy, he can walk and run – 3½ years

“ She tires easily from walking but loves to be active outside in the park. She could not climb until she was 3 – 5 years

“ She can walk short distances but does need a buggy for long distances. She can run in a kind of puppet fashion but cannot jump or skip. She cannot climb stairs and tends to crawl up unless she holds onto the banister whilst being supported by an adult – 6½ years

“ He cannot hop, skip or jump and runs like Frankenstein – 7 years

“ His hypotonia was severe; he could not hold up his head until he was 4 months old. Now, with the help of physiotherapy (core body workouts) and occupational therapy, he can walk and run – 3½ years



3½ years

Development: hand-eye co-ordination and dexterity (fine motor skills) and self care

Hypotonia and joint laxity (see page 10) can also affect fine motor skills in children with 15q24 microdeletions and they may take longer to reach for and grab toys and hold a bottle or cup. This can lead to delays in children being able to self-feed, dress themselves (zips and buttons can be especially problematic) and hold a pen to write or draw. Special chunky cutlery, cups with handles and cutting up food have helped some children. For those children who have problems holding and controlling a writing implement, mastering a keyboard or touch screen computer can often be easier. Tripod grips may help children with their writing skills. (Unique).

child mastered consistent toilet training at three and a half years and another child achieved bowel control at three years (McInnes 2010; Unique). Advice from incontinence services has been reported to be of help, for example drinking more in the day to stretch the bladder and a buzzer to help alert the brain at night (Unique).

“ She was delayed in holding toys, using her hands to play or feed herself and still has difficulty with cutlery. She has difficulty making marks on paper with a crayon or writing tools. But she is making strides in all of these areas and continues to develop on an upward track. She can brush her teeth but needs help – 2½ years

“ She does not have good fine motor skills. She can pinch her thumb and middle finger together and can pick toys up with her finger tips. She uses her entire hand to turn pages in a book when encouraged – 3 years

“ Pencil and fork change easily from left to right hand. He cannot use a knife. He can play with Duplo™ now and do simple puzzles of up to 15 pieces with a little help. His paintings are a lot of lines and circles but he is starting to say what they are. He is in nappies day and night. He can wash his hands with help. He can put on his socks and sometimes his jacket and hat – 5 years

“ She wears a pull-up at night-time but has used the potty during the day from 2½ years although sometimes has accidents if tired or busy in play – 5 years

“ She can hold a cup and drink from it and can eat with her fingers but not with cutlery. She can pick up her toys and loves to turn pages in a book – 6½ years

“ He can eat with a spoon though he can be messy. He is in nappies day and night. A parent brushes his teeth with an electric toothbrush. He helps with dressing – moving arms and legs to help – but cannot dress or undress without assistance – 7 years

Speech and communication

Almost all those with 15q24 microdeletions described so far have a significant delay in language skills. Five of the Unique children have acquired speech to varying extents: one 3 year old has single words and signs whilst another 3-year-old uses 3-4 word sentences together with some signing; a 5-year-old uses four or five word phrases, but struggles with difficult sounds or syllables; a 5½-year-old had speech delay but showed huge improvements after the age of 4 and now speaks a lot and has a full range of language. A 6½-year-old has no speech or signs but has some receptive language and can follow simple instructions. A 15-year old is talking but not always clearly or in full sentences. In the published medical literature many children (20/33) are described as having moderate to severe speech delay; five of these, one of whom is an adult, are non-verbal. Three are described as speaking well and in sentences at 14, 18 years and 33 years. One child has a nasal and hoarse voice and one speaks in a low tone, while one has a high-pitched voice. One child acquired his first words at 12 months and had 10 to 20 words but stopped speaking at 4½ years and now at 5 years only uses two words. In this situation, a picture exchange communication system (PECS) and/or sign language can help children communicate their needs and speech therapy can be enormously beneficial. Computer or phone-based technology is increasingly used. A good example is Proloquo2Go, an Augmentative and Alternative (AAC) solution for iPad, iPhone and iPod touch for people who have difficulty speaking or cannot speak at all (Sharp 2007; Klopocki 2008; Andrieux 2009; Masurel-Paulet 2009; McInnes 2010; Mefford 2011; Magoulas 2012; Unique).

There are many reasons for the speech delay, including the link between the ability to learn and the ability to speak. Those with hearing loss or a high palate may also have specific difficulty with perceiving and producing certain sounds.

“ She uses words and signs. She started speaking at 9 months and now uses 3-4 word sentences. She has articulation problems. Flashcards, iPhone Apps and vocabulary games have all helped – 2½ years

“ She has no words but does have some simple signs – 3 years

“ She makes noises and facial expression which help us to work out how she is feeling and what she wants. She is starting to make some babbling noises. She likes to blow lots of raspberries! – 3½ years

“ He is verbal now and can use 4-5 word sentences. His sounds are still not clear and has difficulty with k, t and others – 5 years

“ She speaks in full sentences but r, f and s are difficult for her to articulate – 5 years

“ She communicates by pushing, pulling and leading. She did use a few signs but as she learns new ones the old ones disappear. Her receptive language is good and she can follow simple instructions but will not wave hello or goodbye and cannot point – 6½ years

“ He is non-verbal at 7 years. He communicates through hand-over-hand (if he wants a door open he will take a hand and lead one to a door and put the hand on the knob). He can communicate through object exchange and limited picture exchange. He can follow simple one-step instructions though can follow multistep instructions for common events.

“ He started talking at 20 months and is talking a lot at 15 years but some speech sounds are not always clear, for example, sh, v, st, sk and sp.

Learning

Learning disabilities are a common finding in children with 15q24 microdeletion syndrome. Some children (17/33) have mild to moderate learning difficulties (with an IQ of 50-70), whereas seven others are described as having moderate to severe learning problems (IQs below 50). A child with a learning difficulty is likely to need some learning support. Many children benefit from attending a special educational school, sometimes from pre-school age or from primary or secondary level. Three Unique children are described as having good memories. Repetition, 1:1 assistance and visual aids such as the use of an iPad are reported by parents to help children learn. Reading and writing are achieved in some children. For example one Unique child was reading at 4½ years, another at 7 years. Some areas of learning may be easier than others (Sharp 2007; Klopocki 2008; El-Hattab 2009; McInnes 2010; Mefford 2011; Magoulas 2012; Unique).

“ She has a severe learning difficulty. She remembers people she sees often and knows routines. She remembers some likeable games (e.g. round and round the garden). She is in a special [educational] school and learns best in a happy, fun environment with people she likes – 3½ years

“ Her memory is one of her greatest strengths. She can memorise short songs and stories after hearing them only once. However, academic things are still difficult for her to learn – 5 years

“ He has a pretty good memory for spaces and people – 7 years

“ As he gets older the gap between him and his peers has widened. It takes him ages to learn something and he can then become frustrated and angry. He can lose something he has learnt. His learning is functioning at about 6-8 years old in the different areas. Maths is the most problematic, but he loves music. He's able to pick up and remember songs very quickly; he feels natural rhythms – 15 years

Medical concerns

■ Lax (hypermobile) joints

Around two thirds of those with 15q24 microdeletion syndrome have joint laxity or loose joints. Some children have joints that are hyperextensible; this ability to extend a joint beyond the normal range may make them prone to injury. Different joints can be affected but most often the hands. One Unique child had lax joints just in the topmost joints of the fingers. Joint laxity in the feet and ankles can make learning to walk more difficult and some children wear supportive shoes with special insoles. Many children have found occupational and/or physiotherapy helpful (Sharp 2007; Klopocki 2008; Andrieux 2009; El-Hattab 2009; Van Esch 2009; McInnes 2010; Mefford 2011; Magoulas 2012; Unique).

■ Vision

Eye findings in 15q24 microdeletion syndrome are common. The most common is strabismus (a squint) where one or both eyes can turn inwards, outwards or upwards (10/33). Several Unique children have a squint. Other problems include nystagmus (rapid uncontrolled eye movements); hypermetropia (long sight); coloboma (a developmental defect in the structure of the eye) and microphthalmia (a developmental disorder that results in small eyes). Two children have anisocoria (pupils that are different sizes at the same time); one of these is reported as having normal vision. One child has papilloedema (swelling of the optic disc) and one child has no stereoscopic (binocular) vision (the single perception of a slightly different image from each eye, resulting in problems with depth perception). One child has severely impaired vision. (Sharp 2007; Klopocki 2008; Andrieux 2009; Masurel-Paulet 2009; Van Esch 2009; McInnes 2010; Mefford 2011; Magoulas 2012; Unique).

■ Hearing

Children with 15q24 microdeletion syndrome can be prone to recurrent ear infections (7/32) and can have some hearing loss (10/33). Hearing impairment is of two types: sensorineural hearing loss (SNHL) and conductive hearing loss. Sensorineural hearing loss occurs when there is damage to the inner ear or to the nerve pathways from the inner ear to the brain, resulting in permanent hearing loss. Several children have this type of hearing loss.

Conductive hearing loss occurs when sound is not conducted efficiently through the outer ear canal to the eardrum and the tiny bones of the middle ear. This type of hearing loss has a number of causes, including fluid in the middle ear (glue ear) or infections (otitis media). Glue ear usually resolves as children get older, secondary to growth and an improving immune system. Therefore, any hearing loss caused by glue ear is usually temporary. However, persistent fluid in the middle ear can reduce a child's hearing at a time that is critical for speech and language development. If glue ear persists, many children will need a grommet, a small ventilation tube, inserted into the eardrum.

“ Grommets were fitted which made a massive difference - 15 years

As well as the 10 cases in the published medical literature, six Unique members have hearing loss, mainly of the conductive type. A large proportion of children with 15q24

microdeletion syndrome have characteristic external ear features, such as large ears, low set ears or fleshy ear lobes (18/33), which are not likely to influence hearing. (Sharp 2007; Andrieux 2009; El-Hattab 2009; Mefford 2011; Magoulas 2012; Unique). One individual diagnosed with oculoauriculovertebral spectrum, a developmental disorder which has characteristic ear features and hearing loss, was subsequently found to have a 15q24 microdeletion (Brun 2012).



3 years

■ Hands and feet

Children and adults with 15q24 microdeletion syndrome may have hands that look different with long, slender, tapering fingers which may be fused (syndactyly) or with curved little fingers (clinodactyly). Short fingers (brachydactyly) have also been reported. Several children have been described with unusually positioned thumbs. These features do not usually cause medical problems but in some cases do have an impact on functionality. Two Unique children have unusual thumbs; one has had surgery to remove an extra bone and the other is due to have surgery to correct a trigger thumb on the left hand. Another Unique child is awaiting a consultation with an orthopaedic consultant to determine if he has sufficient function in his hands or if surgery will improve functionality (Sharp 2007; Klopocki 2008; Andrieux 2009; Masurel-Paulet 2009; Van Esch 2009; Mefford 2011; Magoulas 2012; Unique).

The feet of children with 15q24 microdeletion syndrome may also not be perfectly formed. Some children have long feet with long toes that may overlap or may be fused (syndactyly). Six children have flat feet and one has a high arch (instep). Short and broad toes are also reported (Sharp 2007; Andrieux 2009; McInnes 2010; Mefford 2011; Magoulas 2012; Unique).

■ Genital anomalies


Minor anomalies of the genitals are quite common in babies with 15q24 microdeletion syndrome, most often affecting boys. The most common problem is hypospadias (where the opening of the penis is not at the tip) which affected 8/33 boys in the medical literature and three Unique boys. Hypospadias can be surgically repaired. Microphallus (a small penis) has also been frequently reported. One child had a hooded foreskin at birth; this can be corrected with circumcision. Cryptorchidism (undescended testes) has also been reported. The testicles can be brought down by a straightforward surgical operation if they do not descend of their own accord in time (Sharp 2007; Klopocki 2008; Andrieux 2009; El-Hattab 2009; Masurel-Paulet 2009; Van Esch 2009; Magoulas 2012; Unique).

■ Hernia

Hernias may occur in some children with 15q24 microdeletion syndrome. A hernia occurs when an internal part of the body, such as an organ, pushes through a weakness in the muscle or surrounding tissue wall. The muscles are usually strong enough to keep the organs in place, but if they are not this can cause a hernia. The most common (affecting five children) is an inguinal hernia which is where the bulge is tissue from the intestines and is located in the lower abdomen (groin). An inguinal hernia may require surgery. A congenital diaphragmatic hernia (CDH) has been reported in two children in the medical literature and one Unique child. CDH is where there is a hole in the muscular wall (the diaphragm) which separates the heart and lungs from the contents of the abdomen. This hole is normally present in a baby during early development and usually closes by the end of the third month of pregnancy. In CDH, the hole has stayed open which allows some of the contents of the abdomen (bowel, stomach or liver) to push up

into the chest cavity potentially depriving the lungs of space to develop properly. This means that the lungs may be smaller than they should be. Additionally, CDH may also stop the heart from growing normally. Surgery may be needed to repair the CDH.

One child has a hiatal hernia (the upper part of the stomach pushes upwards into the opening in the diaphragm) and one child has an umbilical hernia (a soft, skin-covered bulge at the belly button (umbilicus) that can look bigger when the baby strains or cries. The bulge contains a small piece of abdominal lining and sometimes part of the abdominal organs. It is caused by incomplete closure of the ring of muscle that the umbilical cord passed through in early life). Umbilical hernias are often quite small and may resolve naturally by the age of 3 or 4 years. Some babies have a larger hernia or one that does not disappear, in which case it can be surgically stitched in a small operation (Sharp 2007; Klopocki 2008; Andrieux 2009; Van Esch 2009; Mefford 2011; Magoulas 2012; Unique).



6 years

■ Breathing

Two Unique babies had breathing problems in the newborn period. One had short episodes of rapid breathing and stridor (a high-pitched sound resulting from turbulent air flow in the upper airway) even when resting. No treatment was necessary as it gradually abated by the age of 3 months. A second child had respiratory problems when born and needed intubation with a ventilator. At the age of 4 months until 2½ years she had oxygen when asleep at night, when a sleep study discovered she had sleep apnoea and she was fitted with a continuous positive airway pressure (CPAP) ventilator. One Unique girl had a persistent cough and used an inhaler. She was referred to a paediatric respiratory consultant and who performed a bronchoscopy (an examination of the major air passages of the lungs) which found that her right lung is at a slightly unusual angle which results in slower drainage. At the age of 3½ years her lungs have compensated for this and she no longer has the cough or needs to use the inhaler (Unique).

One Unique child has tracheomalacia, a weakened tracheal (breathing tube) wall due to softening of the tracheal cartilage; this can result in breathing difficulties – stridor (noisy breathing) and apnea (cessation of breathing, often occurs for short periods of time when sleeping). Another Unique child had a floppy larynx which at the age of 3 years is much better although she snores very noisily when she has a cold (Unique).

It has been reported in the medical literature and at Unique that some children suffer from frequent respiratory infections which often necessitated treatment with antibiotics. One 5-year-old boy also suffers from chronic allergic rhinitis (a blocked or runny nose) and two children have asthma (Sharp 2007; McInnes 2010; Magoulas 2012; Unique).

■ Digestion

One problem is constipation which affects many Unique children with 15q24 microdeletion syndrome. Dietary changes and/or medication can help to manage the problem (Unique).

Two people in the medical literature have been reported to have bowel atresia (a narrow or absent bowel). Four children have an imperforate anus (the opening to the anus is missing or blocked) which can be corrected surgically (Sharp 2007; Andrieux 2009; Mefford 2011; Magoulas 2012; Unique).

■ Palate

One Unique child has a cleft palate (an opening in the roof of the mouth due to the palate does not form correctly during development). A cleft palate can be corrected surgically. A few children with 15q24 microdeletion syndrome have been reported to have a high palate. A cleft or high palate can contribute to the early feeding difficulties seen in children (Andrieux 2009; Van Esch 2009; Magoulas 2012; Unique).

■ Teeth

Generally speaking, children with chromosome disorders appear to have somewhat more dental problems than their peers. One boy needed hospitalisation at the age of 4 for the treatment of severe dental cavities. Two Unique children have particularly small teeth which are very crowded in one child. Another Unique child also has crowded teeth. One Unique child has a single central incisor. Regular and high quality dental care is recommended (McInnes 2010; Magoulas 2012; Unique).

■ Spine

Eight children have been reported to have curvature of the spine (scoliosis). One Unique child wears a rigid foam jacket when sitting and another has physiotherapy (Sharp 2007; Klopocki 2008; Masurel-Paulet 2009; Van Esch 2009; McInnes 2010; Mefford 2011; Magoulas 2012; Unique).

■ Heart

Heart problems have been reported in a few children with 15q24 microdeletion syndrome. One child has a ventricular septal defect (VSD) which is a hole in the wall between the two pumping chambers of the heart (ventricles). This allows blood to flow from the left to the right chamber, increasing the blood flow to the lungs. Treatment is determined individually. Small VSDs may close spontaneously; a larger VSD usually needs surgical repair to prevent lung problems that would develop from extra blood flow. Two children have tetralogy of Fallot which is a complex heart condition involving both a VSD and an obstruction just below the valve in the artery that leads to the lungs. Blue (deoxygenated) blood cannot easily get to the lungs to pick up oxygen and some of it flows through the hole into the other pumping chamber from where it is pumped around the body. The majority of babies with tetralogy of Fallot successfully undergo surgery in the first year of life. One child has patent ductus arteriosus (PDA), a heart defect that occurs when one of the foetal blood vessels, the ductus arteriosus, does not close at birth. Four children have mild pulmonary stenosis (a narrowing of the pulmonary valve (a flap-like structure that allows blood to flow in one direction)), meaning that the heart has to work harder to pump blood which results in breathlessness). A Unique child has coarctation of the aorta (a narrowing of part of the aorta which is the major artery leading out of the heart) which was detected during pregnancy by an ultrasound scan at 28 weeks. It was surgically repaired at 5 days old (Sharp 2007; Andrieux 2009; El-Hattab 2009; Mefford 2011; Magoulas 2012; Unique).

■ Skin

Several children with 15q24 microdeletion syndrome have dry skin. Two Unique children have eczema. One Unique child has keratosis pilaris (a common skin condition in which a protein in the skin called keratin forms hard plugs within hair follicles resulting in a fine, bumpy texture to skin) on his arms and legs. Seven children in the published medical literature have café au lait spots (pigmented birthmarks), one of whom also has

acanthosis nigricans (a skin disorder in which there is darker, thick, velvety skin in body folds and creases). Another child just has acanthosis nigricans (Andrieux 2009; El-Hattab 2009; Mefford 2011; Unique).

■ Seizures

Seizures, or fits, are caused by a change in electrical activity in the brain. There are a number of different types, including epilepsy. Children with 15q24 deletion syndrome may have an increased risk of seizures. One Unique child had seizures from the age of 7 months but at 3 years the seizures are under control with medication. At age 12, another Unique child had several seizures over a short time period; these were attributed to the onset of puberty. Once the dose of medication was increased he was stable and several years later, with no current medication, has had no more fits (Unique). Another four individuals (reported in the medical literature) also suffer from seizures. One of these was described as having one seizure at 25 years (Mefford 2011).

Magnetic resonance imaging (MRI) is a non-invasive medical imaging technique which uses radio and magnetic waves to provide a very detailed image of organs, bones and tissues inside the body. Brain MRI scans are regularly performed on children with 15q24 microdeletion syndrome. Many of these show normal brain structure. Twelve children have been shown to have structural changes, some of which may be related to seizures (Mefford 2011; Magoulas 2012; Unique).

■ Other

Other less frequent findings are one boy with an enlarged liver; one boy with an enlarged spleen and a Unique child with an ectopic (unusually positioned) right kidney (which is functional and so has needed no treatment) (Sharp 2007; Klopocki 2008; El-Hattab 2009; Unique).

Behaviour

In general children with 15q24 microdeletion syndrome are happy, affectionate and sociable. However, they are as vulnerable to frustration as other children with a communication difficulty and a small minority succumb to temper tantrums and aggression. One child has sensory processing disorder. This occurs when the brain is unable to integrate information received from the body's five senses – sight, sound, smell, taste and touch. Another child has tactile defensiveness (a tendency to react negatively or with alarm to sensory input which is generally considered harmless or non-irritating) and can occasionally be aggressive. One child described in the medical literature had a difficult temper and threw frequent tantrums and was very restless and hyperactive. He could not modulate his behaviour in emotional situations and displayed aggressive behaviours towards himself and/or others when happy or sad. Obsessive compulsive behaviour was reported in one child and another had food-seeking behaviour. One child, when in an environment which is too busy or noisy, will lie down and stimulate himself to forget everything going on around him. When this happens, his parents and staff at his nursery will take him to a neighbouring room or quiet corner. Encouraging calm environments, in general, is reported to be beneficial (El-Hattab 2009; Van Esch 2009; McInnes 2010; Mefford 2011; Magoulas 2012; Unique).

Additionally, affected children are more likely than children without 15q24 microdeletion syndrome to have attention deficit hyperactivity disorder (ADHD) which is characterised by restlessness and a short attention span or have difficulties with concentration. Autistic spectrum disorder (ASD) has also been reported in eight people with 15q24 microdeletion syndrome. Autistic traits include hand flapping; self stimulating behaviours including

spinning, hitting objects or looking at their hands; repetitive behaviours; difficulty adjusting to new routine or environment; poor social awareness and a lack of eye contact. One boy had constant smiling and inappropriate laughing and three others are reported to have happy facial expressions. A diagnosis of autism can be extremely helpful in accessing services and tailoring the educational and behavioural therapy to meet the specific needs of a child with autism. Parents have reported that a behaviour management system, both at school and at home, may work for older children and teenagers, for example, point systems that result in a special treat or pocket money rewards (Sharp 2007; Van Esch 2009; McInnes 2010; Mefford 2011; Magoulas 2012; Unique).

Children with 15q24 microdeletion syndrome seem to share a great love of music.

“ When he is not in pain from reflux or constipation he is a happy and calm child and enjoys watching things and people and is generally quite passive – 14 months

“ She has a sweet and caring disposition. She is quite funny and so adorable. She really is a delight even if she has a bit of a temper. She can be shy and moody and has tactile defensiveness. She does not like surprise touches and can be bossy and territorial – 2½ years

“ She is an extremely happy and loving girl. She never gets upset and hardly ever cries. She is loved by all that meet her – 3 years

“ She loves TV. She really likes 3D characters and real people (as opposed to 2D cartoons), and if there is singing or music then all the better – 3½ years

“ He is a happy child. He has recently started communicating and playing with other children. It is hard for him to concentrate on one thing – 5 years

“ She thrives on social activities and loves, loves, loves being active with other children. She is getting better at emotional regulation but still needs lots of help and reminders. She can role play but has a difficult time with back and forth play. She is affectionate and very sensitive to one's mood. She loves to perform. She loves water play, sand and swimming – 5 years

“ She loves anything musical. She is always happy, very affectionate and always laughing or smiling. She does not have tantrums – 6½ years

“ He is a happy and very social child. He has an easy smile and an easy-going disposition. He does not appear to engage in imaginative play. Within the past 6 months he has started to get interested in television. He likes toys that have buttons that he can press for sound and music. He loves water and sand and is very tactile. He likes leafing through books and has favourite books and magazines. He does not prefer routine and likes to be out and about. He is an incredible flirt and his smile and laugh are contagious. At school they say he can get the whole class in fits of laughter every day. He is something of a local celebrity in the places we most frequent. Although generally happy and easy-going he does have his moments. He went through a stage of interactive hand flapping and will sometimes hit, especially if upset. When he hits we hold his hands gently and look away for a minute or two and try to start the interaction from the beginning. He does not get a big response for bad behaviour but is instead ignored for very short periods of time. He likes attention and generally this works – 7 years

“ He was tested for ADHD when younger but was not diagnosed. He now only gets aggressive when overtired. His behaviour has calmed a lot since he attended schools which can cater for his needs. He needs praise and reminding to stay on track. He needs firm boundaries so he knows where he is – 15 years

“ He has a lovely operatic singing voice which we have only just discovered – 15 years

Sleep

Most children with 15q24 microdeletion syndrome have no trouble going to sleep and staying asleep. However, sleep problems affect a few children. One Unique child is often woken from sleep by reflux pain. Another child needs someone to stay with him until he falls asleep. A 5-year-old boy described in the medical literature had difficulty falling and staying asleep. One child has sleep apnea (transient cessation of breathing) which disappeared after his enlarged tonsils and adenoids were removed (Sharp 2007; McInnes 2010; Unique).

“ He has always slept well. He still has a daytime sleep at the weekend and sometimes after school. He can get extremely tired very quickly – 15 years

Puberty and fertility

Due to the small numbers of people so far reported with 15q24 microdeletion syndrome, in particular those that have gone through puberty, there is very little information on puberty. No one with 15q24 microdeletion syndrome has reportedly had a child (Mefford 2011; Magoulas 2012).

Adults with 15q24 microdeletion syndrome

Six adults have been described in the medical literature. One is a 33-year-old man with a severe learning difficulty and behavioural problems. Another adult (a 24-year-old) also has severe learning difficulties with no verbal communication whilst others have mild to moderate learning difficulties with some speech. One can speak in sentences. Some aggressive and obsessive compulsive behaviour is described in several adults.

The features of the hands, feet and face described above were also evident in adults. Hernias were detected in two adults; one man had inguinal hernias on both sides of the abdomen whilst another man had a congenital diaphragmatic hernia that went unnoticed for more than 30 years. Two adults had profound hearing loss.

There are certainly more people, including adults, with 15q24 microdeletion syndrome. As the molecular techniques which are needed to detect this microdeletion become more commonplace, further people are very likely to be diagnosed (Sharp 2007; Van Esch 2009; Mefford 2011). Based on the common features of 15q24 microdeletion syndrome, children and adults should receive thorough developmental evaluations, physical, occupational and speech therapies and regular eyesight and hearing tests (Mefford 2011). Additional genital/ cardiac examinations and neurological examination/brain scans are also likely to be required.

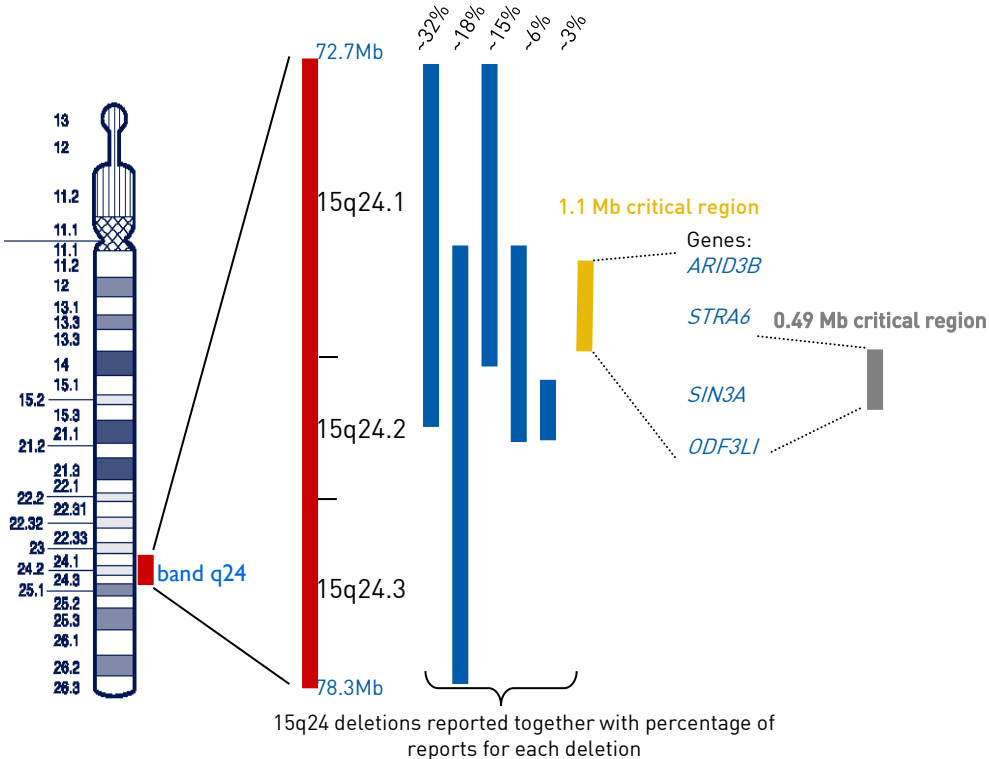
Ongoing research involving 15q24

A 15q24 microdeletion is tiny, so it can only be found using molecular techniques such as MLPA or microarrays (array-CGH) or targeted cytogenetic testing using FISH. These techniques show whether particular genes are present or not. The features of 15q24 microdeletion syndrome are likely to be a result of the loss of a number of different genes found in this region. No single gene has so far been shown to produce the characteristic features of 15q24 microdeletion syndrome (Mefford 2012).

The 15q24 microdeletions range from 266kb to 6.1Mb (with most deletions at least partly overlapping). One study, involving 15 people, found nine distinct deletions with different breakpoints (Mefford 2011). It has been noted that a region of 1.1 Mb on 15q24.1q24.2 in which 26 genes are located is deleted in the majority of those reported so far (11/15 Mefford 2011). Although this region may be a critical one for 15q24 microdeletion syndrome, no one with a deletion involving only this critical one has been reported to date (Mefford 2012).

Longer deletions may involve 50 or more genes. Notably, two children have small deletions that lie outside the more typical 1.1 Mb region and involve a small number of genes: 5-15. These two patients had milder features of the syndrome with, for example, mild learning difficulties and, unlike the majority of individuals with longer deletions, both have developed reasonable speech (Mefford 2011).

Determining the exact size of the deletion is necessary for identifying critical regions and genes that may contribute to the features of 15q24 microdeletions (Andrieux 2009; El-Hattab 2010; Mefford 2011). It has been hypothesised that a gene in a 490kb region (see diagram) is responsible for the hypospadias commonly seen in boys with 15q24 microdeletion syndrome because a boy with a small deletion which did not include this region had no genital anomalies whereas boys with this region missing did. This 490kb region contains 10 genes including *SIN3A* and *ODF3L1* which both code for proteins found in the testis and may potentially be involved (Andrieux 2009).



Eye anomalies are often seen in those with 15q24 microdeletion syndrome and located on 15q24.1 is the gene *STRA6* which has been shown to be involved in a developmental eye disorder, microphthalmia type 9. Mice with *STRA6* missing develop an eye disorder and also develop cardiovascular problems and diaphragmatic hernias. This gene may therefore potentially play a role in the eye anomalies, cardiac anomalies and/or hernias seen in those with microdeletions of 15q24. Another candidate gene is *CPLX3* which is expressed in the brain and eye and regulates nerve impulses (Andrieux 2009; El-Hattab 2010, Mefford 2012).

Mice that are missing the gene ARID3B have cardiovascular anomalies so this gene may be involved in the cardiac problems that sometimes affect people with 15q24 microdeletion syndrome (Takebe 2006).

It is important to remember that while identifying the gene(s) responsible for certain features of the 15q24 microdeletion syndrome is valuable and may help guide future studies, it does not lead directly to immediate improved treatment. Additionally, even if the supposedly responsible gene is missing it does not always mean that the associated feature(s) will be present. Other genetic and environmental factors often have a role in determining the presence or absence of a particular feature.

Why did this happen?

A blood test to check both parents' chromosomes is needed to find out why the 15q24 microdeletion occurred. In all reported cases so far the microdeletion occurred when both parents have normal chromosomes. The term that geneticists use for this is *de novo* (dn) which means 'new'. *De novo* 15q24 microdeletions are caused by a change that occurred when the parents' sperm or egg cells formed or possibly during formation and copying of the early cells after the egg and sperm joined.

As a parent there is nothing you did to cause the 15q24 microdeletion and nothing you could have done would have prevented it from occurring in your baby.

No environmental, dietary or lifestyle factors are known to cause these chromosome changes. No one is to blame when this occurs and nobody is at fault.

“ Our case is *de novo* and not an inherited condition. There is nothing we could have done to prevent this – it is just one of those things. Try to find the positive in your own child and focus on that – 15 years

Can it happen again?

Where both parents have normal chromosomes (as in all cases reported so far), it is unlikely that another child will be born with a 15q24 microdeletion or any other chromosome disorder. Very rarely (less than 1%), both parents have normal chromosomes by a blood test, but a few of their egg or sperm cells carry the 15q24 microdeletion. This is called *germline mosaicism* and it means that parents whose chromosomes appear normal when their blood is tested can have more than one child with the deletion.

In families where the 15q24 microdeletion has been inherited from a parent, the possibility of having another child - either a girl or a boy - with the 15q24 microdeletion rises to 50% in each pregnancy. However, the effect of the microdeletion on the child's development, health and behaviour cannot be reliably predicted.

Your genetics centre should be able to offer counselling before you have another pregnancy.

Notes

Inform Network Support



Understanding Chromosome & Gene Disorders

Rare Chromosome Disorder Support Group,

The Stables, Station Rd West, Oxted, Surrey. RH8 9EE. UK

Tel: +44(0)1883 723356

info@rarechromo.org | www.rarechromo.org

There is a Facebook group (called 15 q 24 microdeletion; please be sure to include the spaces between the 15, the q, and the 24) for families affected by 15q24 microdeletions www.facebook.com

Join Unique for family links, information and support.

Unique is a charity without government funding, existing entirely on donations and grants. If you can please make a donation via our website at www.rarechromo.org/donate

Please help us to help you!

Unique mentions other organisations' message boards and websites to help families looking for information. This does not imply that we endorse their content or have any responsibility for it.

This leaflet is not a substitute for personal medical advice. Families should consult a medically qualified clinician in all matters relating to genetic diagnosis, management and health. The information is believed to be the best available at the time of publication. It was compiled by Unique and reviewed by Dr Evan Eichler, University of Washington, Dr Heather Mefford, Seattle Children's Hospital and University of Washington, USA and by Professor Maj Hultén, Professor of Medical Genetics, University of Warwick, UK

2011 Version 1 (SW)

2012 Version 1.1 (SW/CW)

Copyright © Unique 2018